

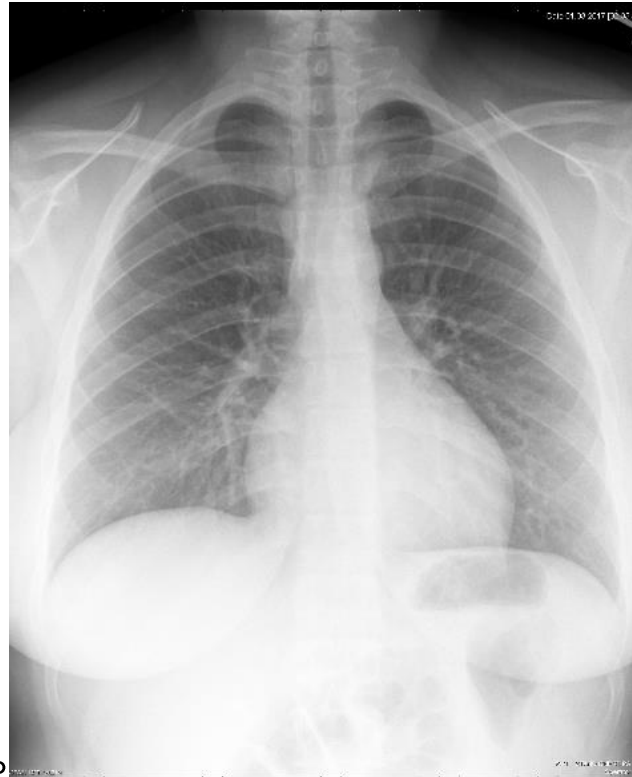
Technologist Review System Chest Radiography

Category	A	B	Comments
All Exams			
Complete exam	All projections	Missing any of the projections	Patient information form should also be included for DCMC exams.
Overlying material removed	No overlying material or trivial overlying material which does not obscure anatomy	Overlying material which obscures anatomy	More than minimal overlying clothing may mimic pneumothorax, pulmonary nodules, fracture lines, etc. Note that gown snaps may obscure lung nodules.
Motion artifact	None or trivial (questionable) motion artifact which does not obscure anatomy	Motion artifact which obscures anatomy	Motion artifact obscures lung markings, bone margins, the cardiac margin, etc.
AP			
Inclusion of both costophrenic angles and both apices	Yes	No	Nodules, consolidation, effusions, and pneumothoraxes may be missed if the entire lung is not included on the exam.
Rotation (measured from the clavicle head to midline).	< 2 cm side to side difference	> 2 cm side to side difference	Rotation makes evaluation of cardiac and mediastinal contours, nodules, masses, and consolidation difficult.
Inspiration	> 8 posterior ribs seen	8 or fewer posterior ribs seen	Non-inspiration films crowd pulmonary vasculature and lung markings, simulating pulmonary edema and consolidation as well as obscuring lung nodules.
Penetration	Visualization of the carina.	Lack of visualization of the carina.	Poor penetration obscures lung fields and mediastinal structures. The carina is a necessary landmark for endotracheal and tracheostomy tubes.
Lateral			
Exclusion of arms from anterior clear space	Yes	No	Anterior clear space needs to be well seen to exclude tumors and consolidation.

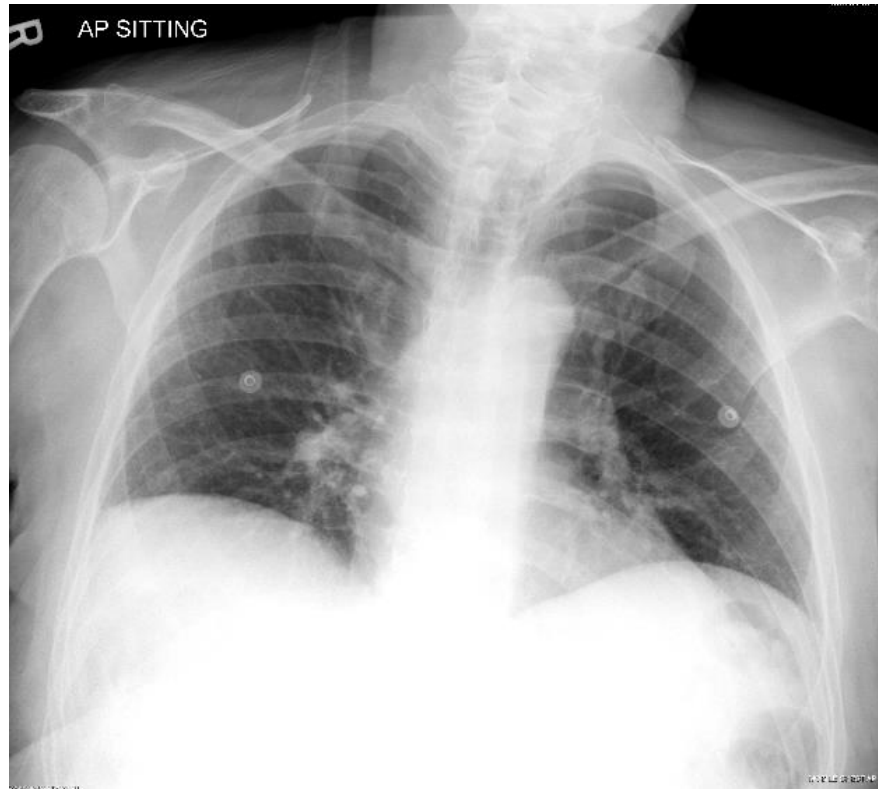


TRS Chest Radiography 03-08-18

Page 2



AP

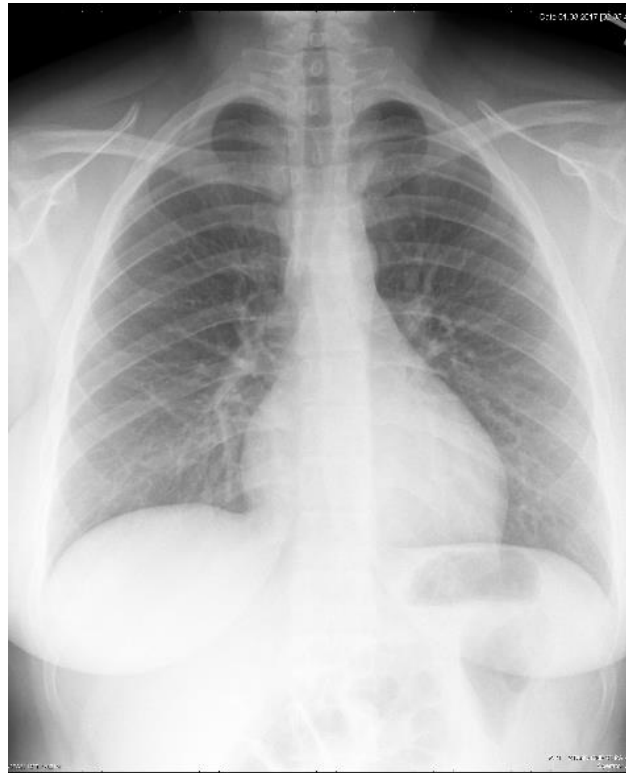


A: No overlying material

B. Overlying material which obscures anatomy (snaps)

Category	A	B
Overlying material removed	No overlying material or trivial overlying material which does not obscure anatomy	Overlying material which obscures anatomy

AP



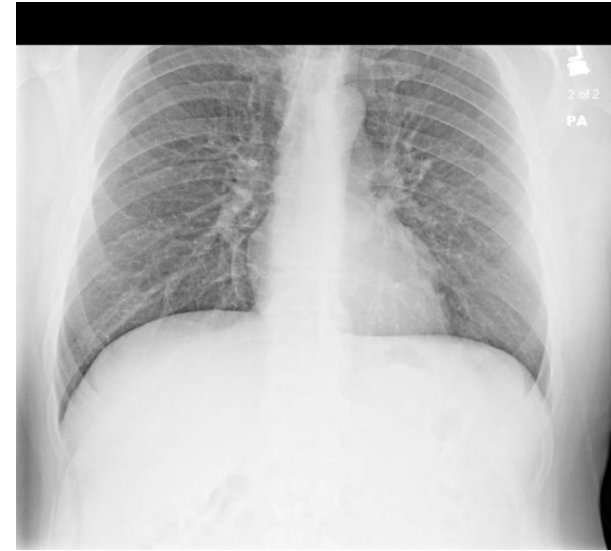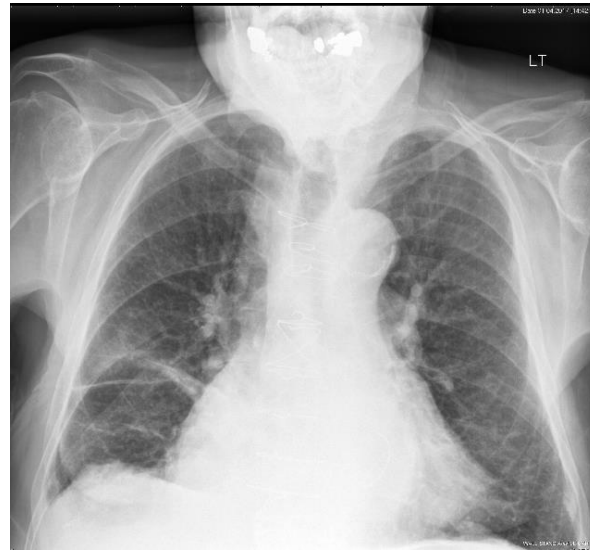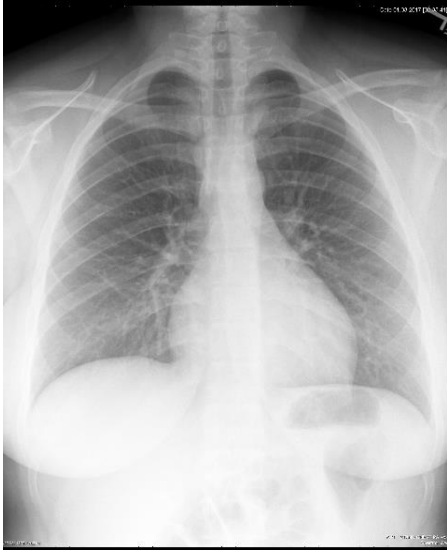
A: No motion artifact

B. Motion artifact

Category	A	B
Motion artifact	None or trivial (questionable) motion artifact which does not obscure anatomy	Motion artifact which obscures anatomy



AP



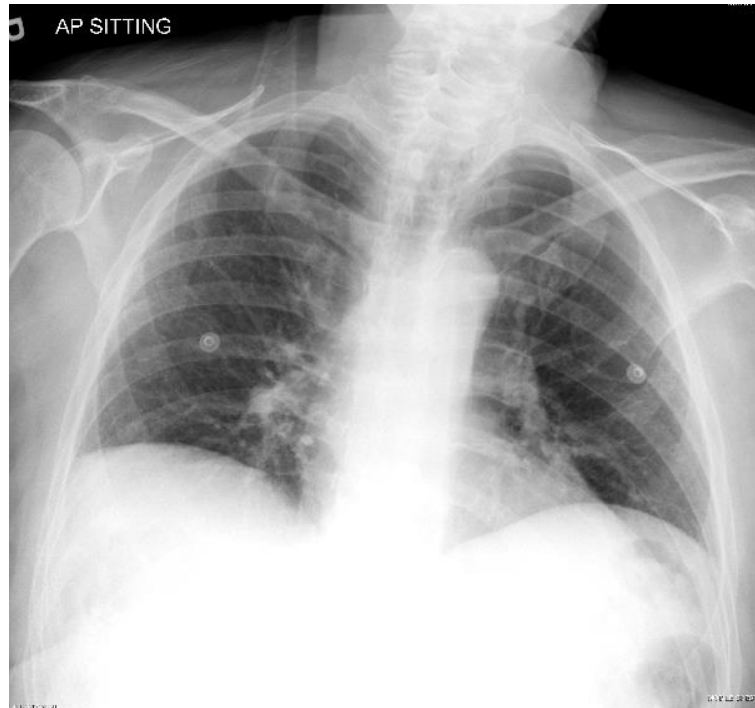
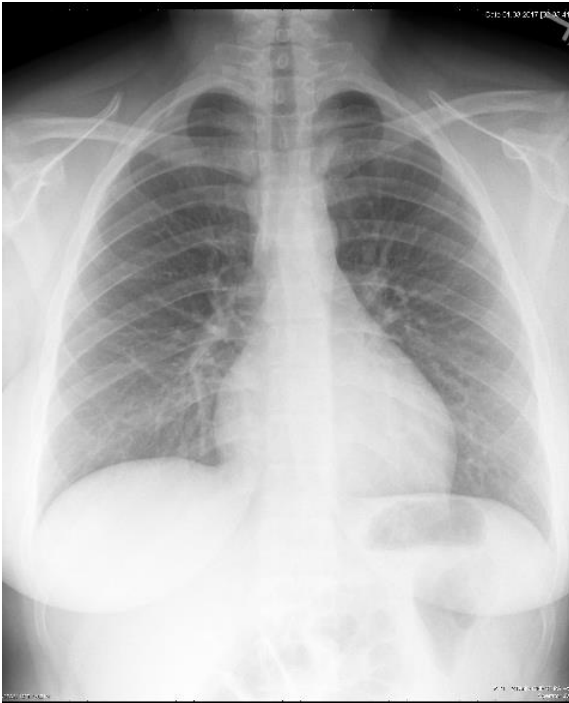
A: Both CPAs & lung apices.
angle.

B: Exclusion of the lung apices.

C. Exclusion of a costophrenic

Category	A	B
Inclusion of both costophrenic angles and both apices	Yes	No

AP

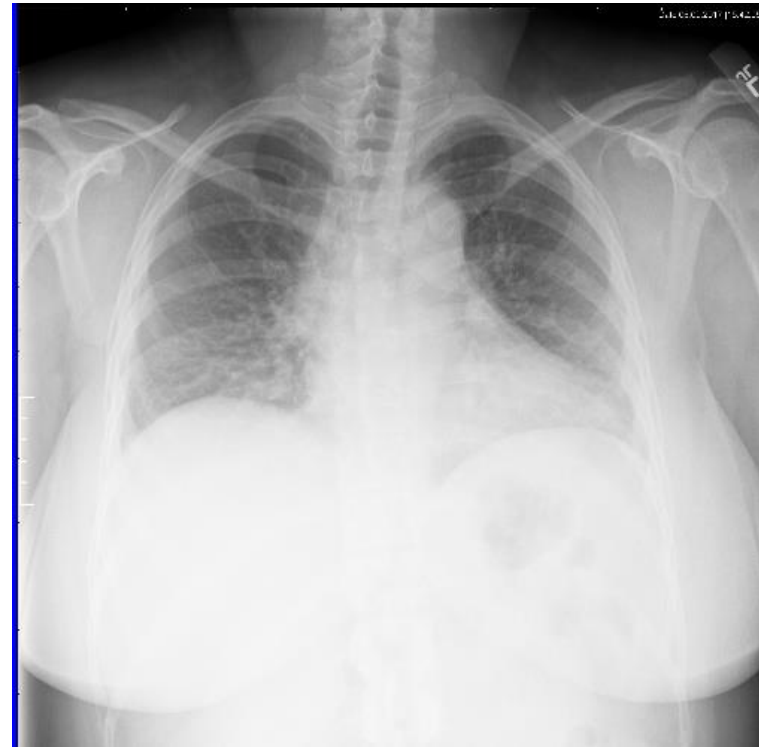
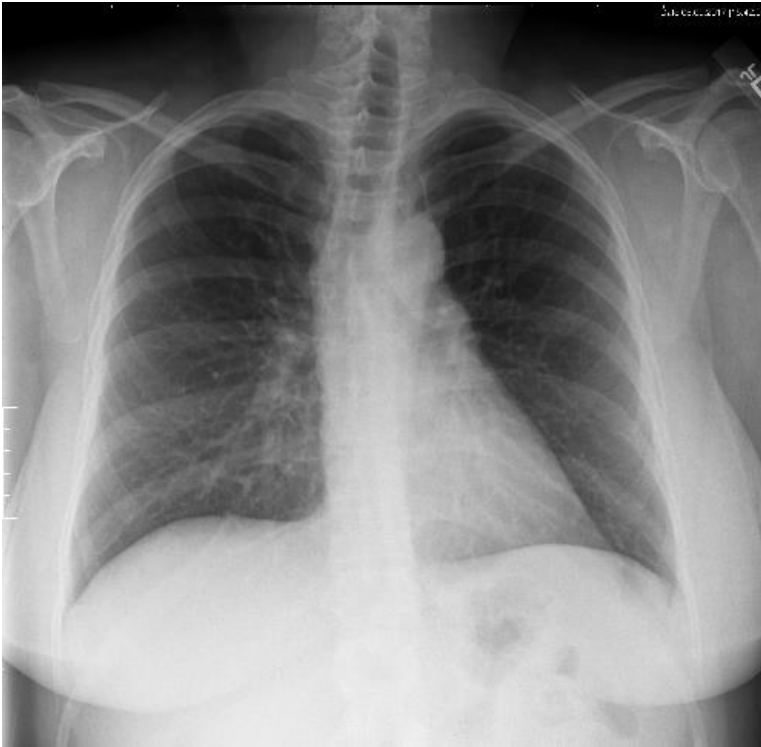


A: < 2 cm side to side difference

B. > 2 cm side to side difference

Category	A	B
Rotation (measured from the clavicle head to midline)	< 2 cm side to side difference	> 2 cm side to side difference

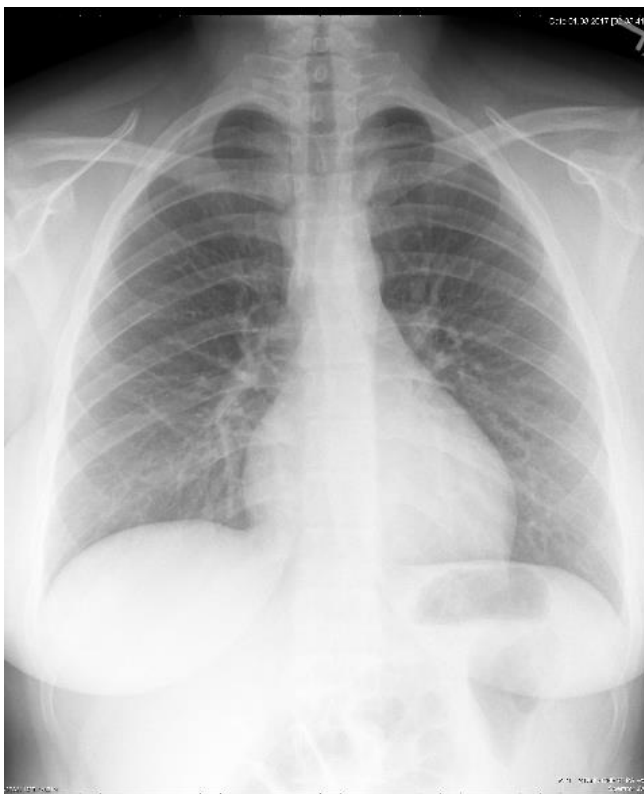
AP



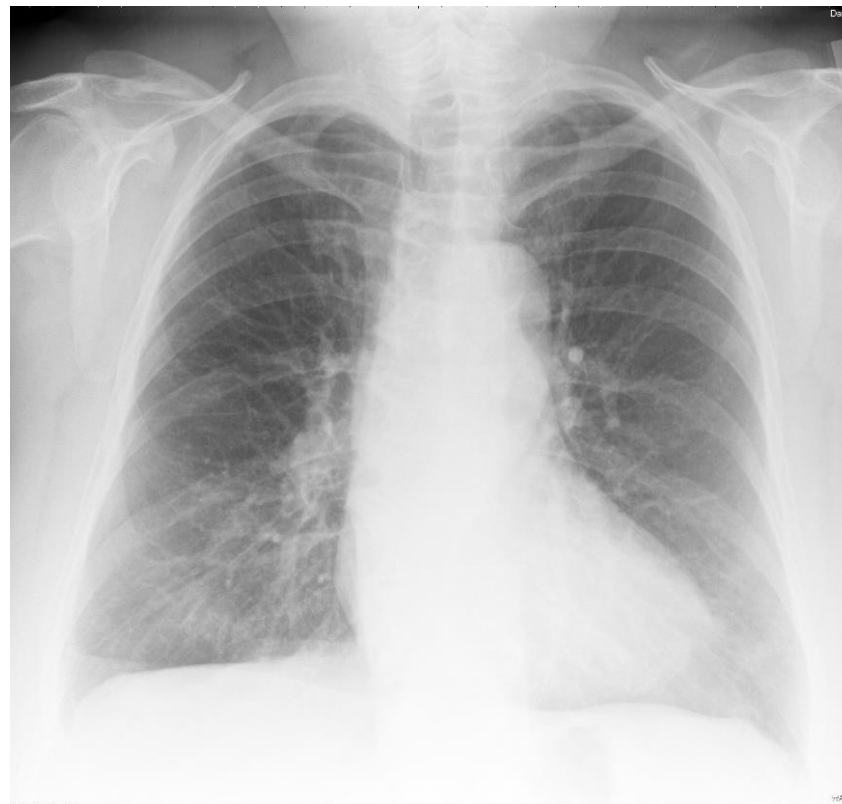A: > 8 (in this case, 9) posterior ribs seen. Repeat of exam shown in "B:" B: 8 or fewer posterior ribs seen (same patient as in "A:").

Category	A	B
Inspiration	> 8 posterior ribs seen	8 or fewer posterior ribs seen

AP



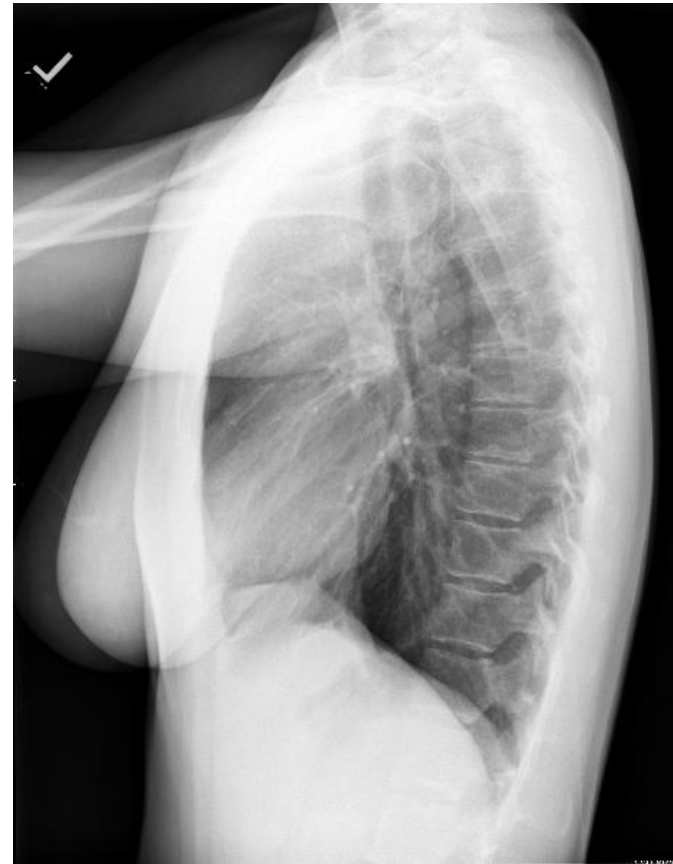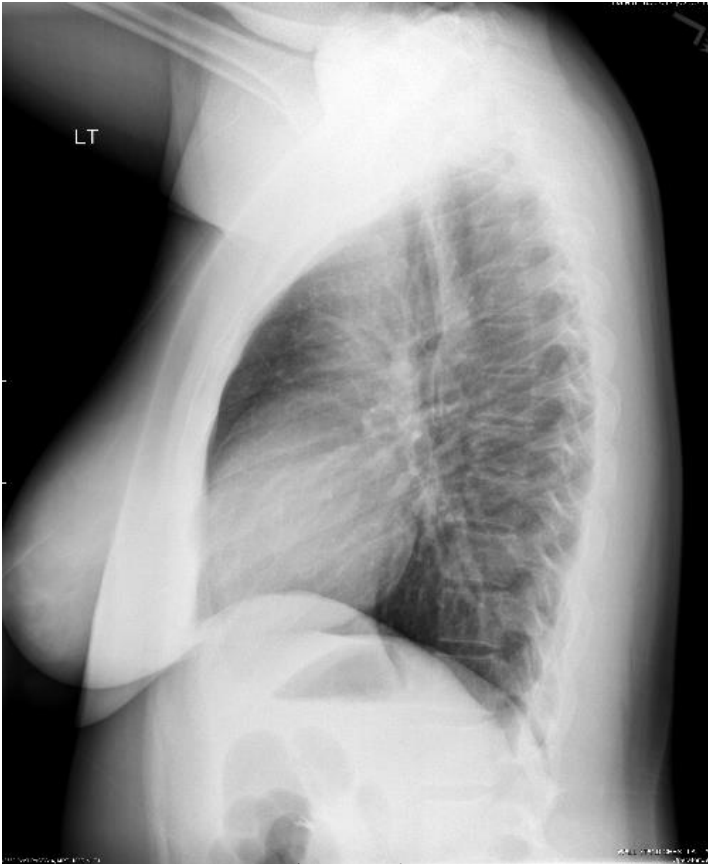
A: Visualization of carina.



B. Lack of visualization of the carina.

Category	A	B
Penetration	Visualization of the carina.	Lack of visualization of the carina.

Lateral



A: Arms excluded from the anterior clear space

B: Arms overlapping the anterior clear space

Category	A	B
Exclusion of arms from anterior clear space	Yes	No